



SRI VENKATESWARA DENTAL COLLEGE & HOSPITAL



(A unit of VELS Group, Pallavaram)

Approved by Government of Tamilnadu (Lr. No. TN35013/MCA-2/2003; dt.7.9.2006) Approved by Dental Council of India, New Delhi
Approved by Government of India Vide. F. No. V.12017/3/2003-DE, dt. 14.07.2007 & dt.08.11.2011. Ministry of Health & Family Welfare

Affiliated to the Tamil Nadu Dr.MGR Medical University

NAAC ACCREDITED

Off OMR, Near Navalur, Thalambur, Chennai - 600 130

Phone.:7449000052 / 53 / 54 Fax : 044 -2743 5770 E-mail : info@svdentalcollege.com www.svdentalcollege.com

STUDENTS CENTRIC TEACHING METHODS

The students are trained in the subject through participatory learning. Quizzes are conducted to make the classes interactive. Problem solving methodologies are inculcated by regular case discussions and various case discussions are done in clinical society meeting where the students learn interdisciplinary approach towards various case scenarios.

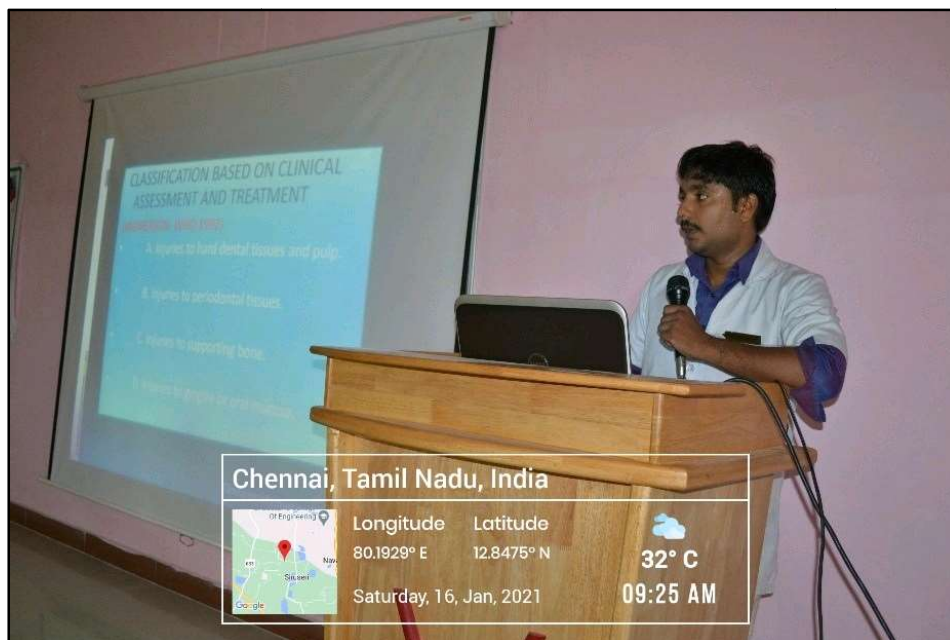PRINCIPAL

SRI VENKATESWARA DENTAL COLLEGE & HOSPITAL

OFF. OMR NEAR - NAVALUR

THALAMBUR, CHENNAI-600 130.

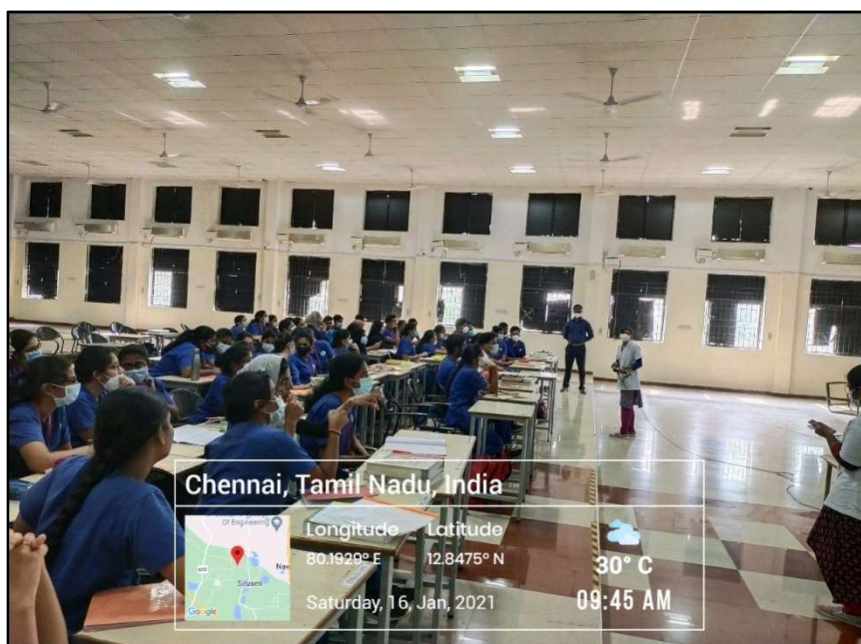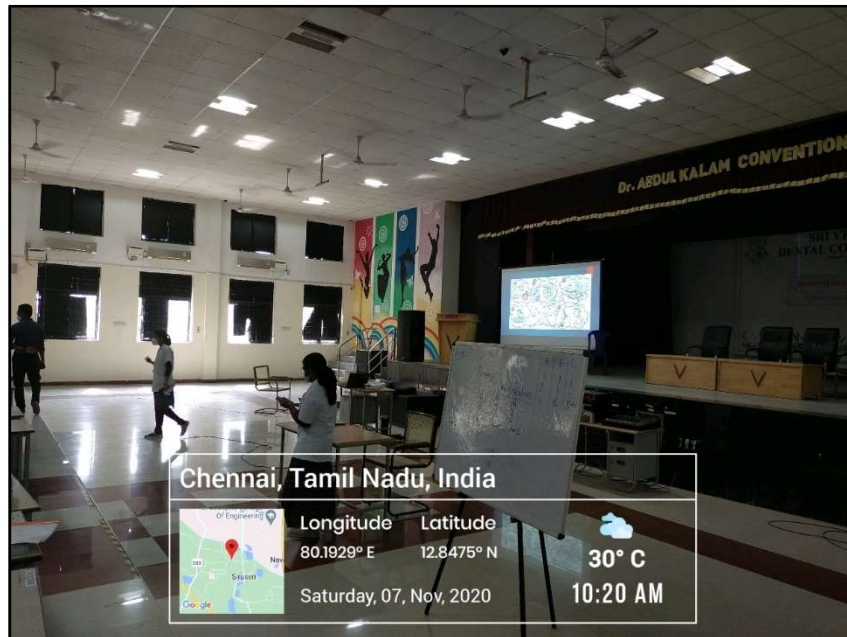
INTERDISCIPLINARY LEARNING



PRINCIPAL

SRI VENKATESWARA DENTAL COLLEGE & HOSPITAL
OFF. OMR NEAR - NAVALUR
THALAMBUR, CHENNAI-600 130.

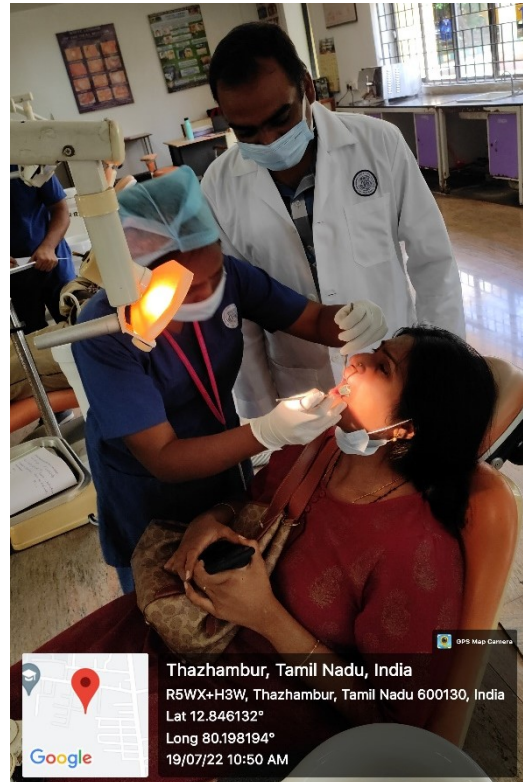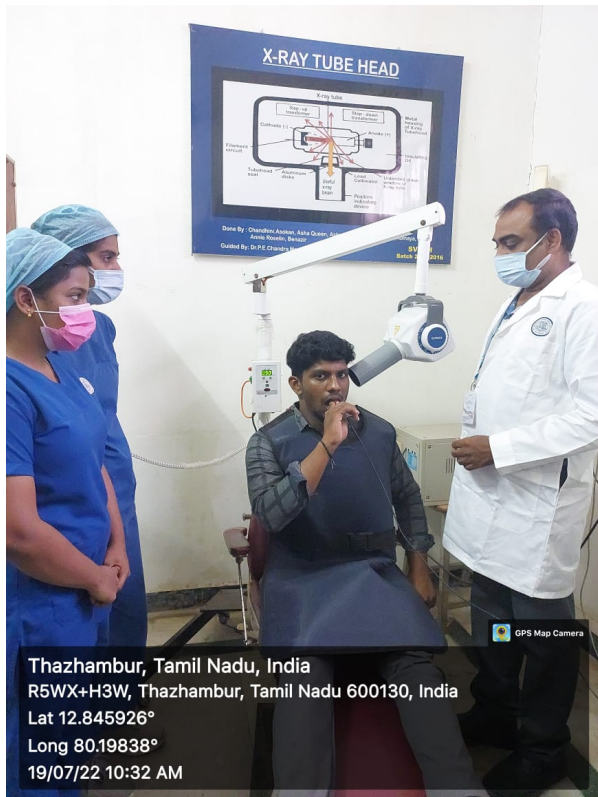PARTICIPATORY LEARNING



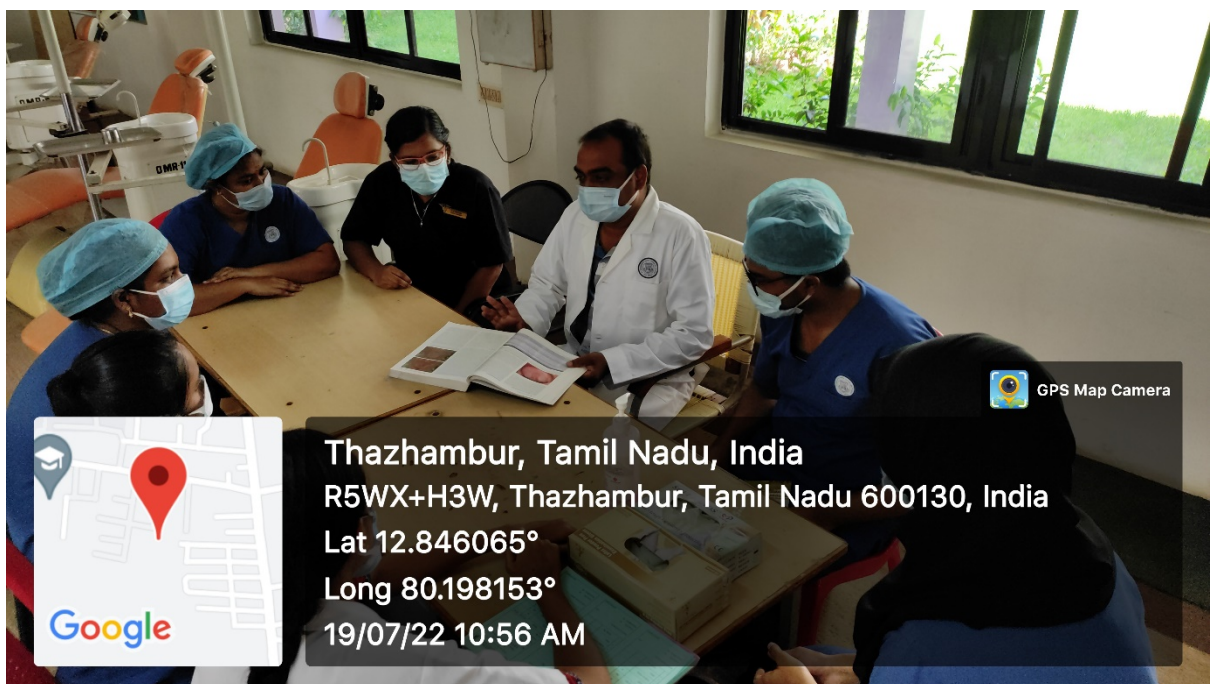PRINCIPAL

SRI VENKATESWARA DENTAL COLLEGE & HOSPITAL
OFF. OMR NEAR - NAVALUR
THALAMBUR, CHENNAI-600 130.

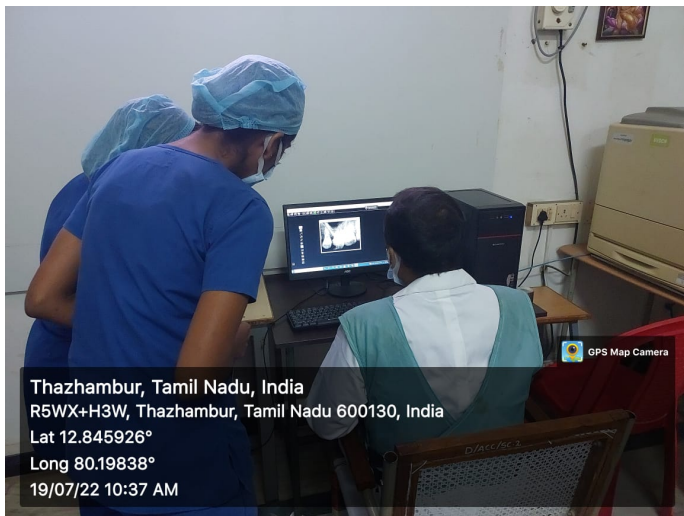Radiographic training



Case discussions



Radiographic training Radiographic training



Radiographic training



ENDODONTIC OPERATING MICROSCOPE



CASE DISCUSSION



A. J. Jeyaraj

PRINCIPAL
SRI VENKATESWARA DENTAL COLLEGE & HOSPITAL
OFF. OMR NEAR - NAVALUR
THALAMBUR, CHENNAI-600 130.

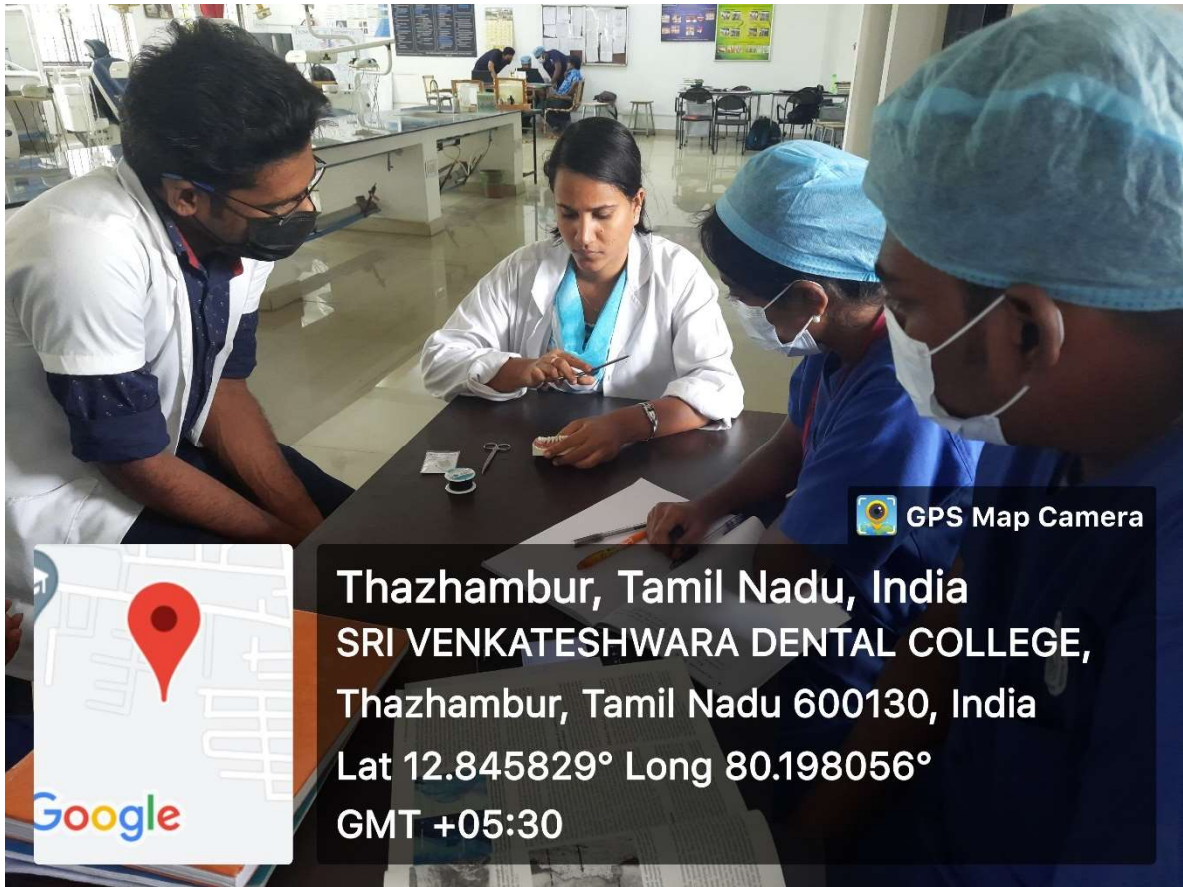
PRE-CLINICAL DEMONSTRATION



PRE-CLINICAL DEMONSTRATION



SUTURING IN MODELS



PRINCIPAL
SRI VENKATESWARA DENTAL COLLEGE & HOSPITAL
OFF. OMR NEAR - NAVALUR
THALAMBUR, CHENNAI-600 130.

POWERPOINT PRESENTATION



CHALK AND TALK PRESENTATION

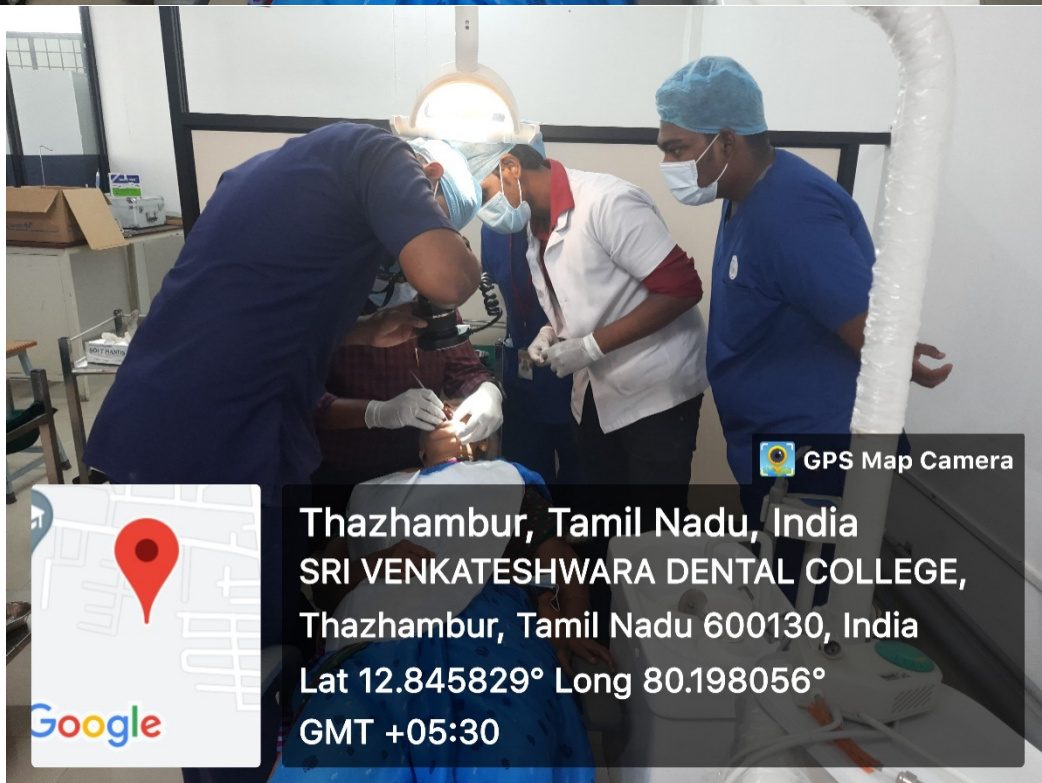
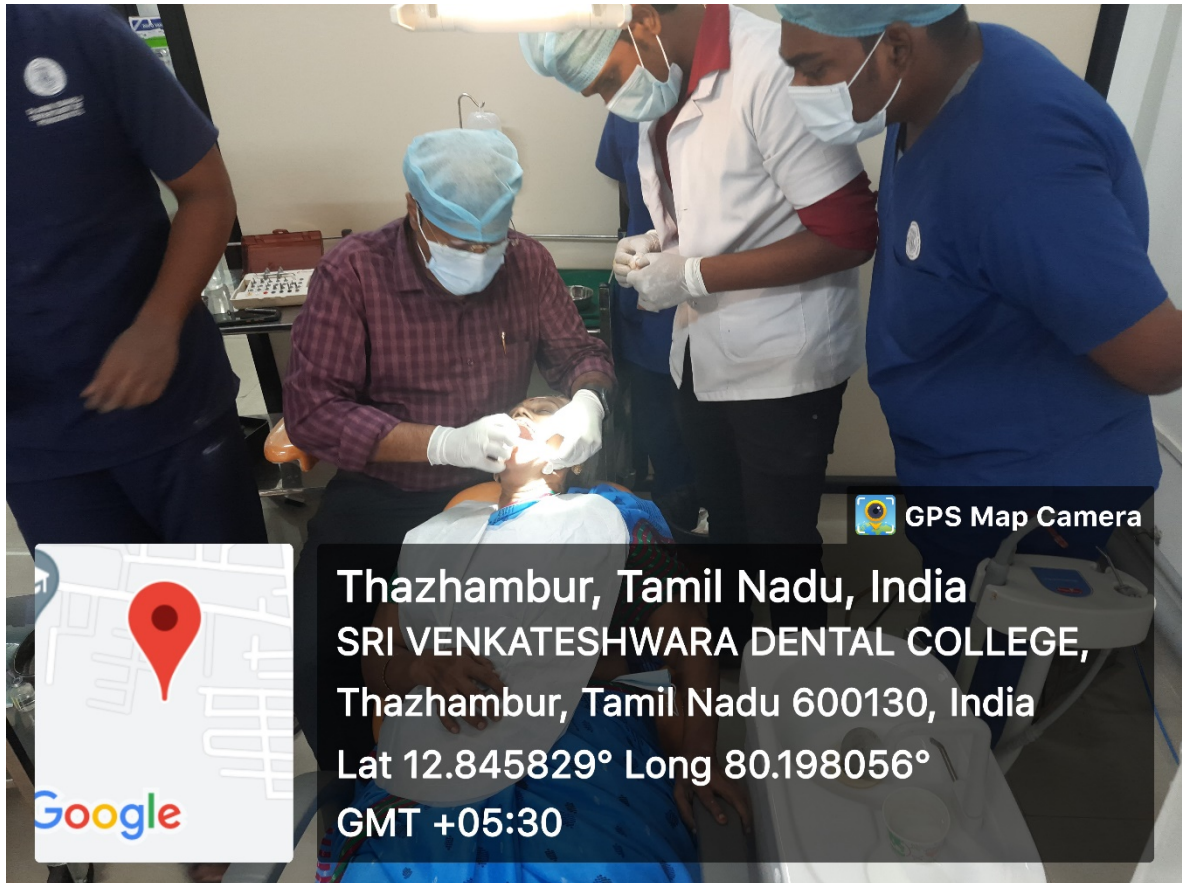

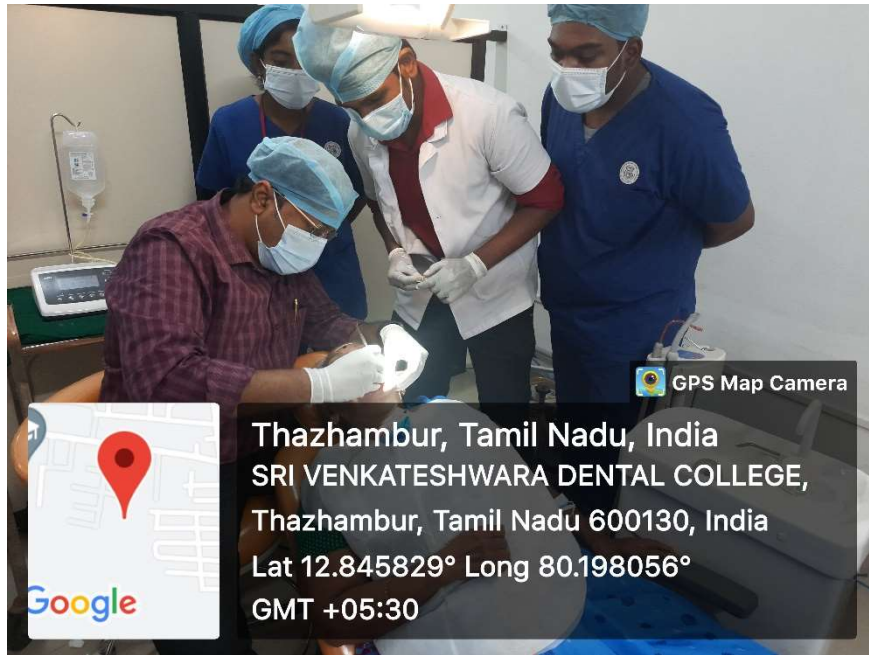
PRINCIPAL
SRI VENKATESWARA DENTAL COLLEGE & HOSPITAL
OFF. OMR NEAR - NAVALUR
THALAMBUR, CHENNAI-600 130.

CLINICAL DEMONSTRATION

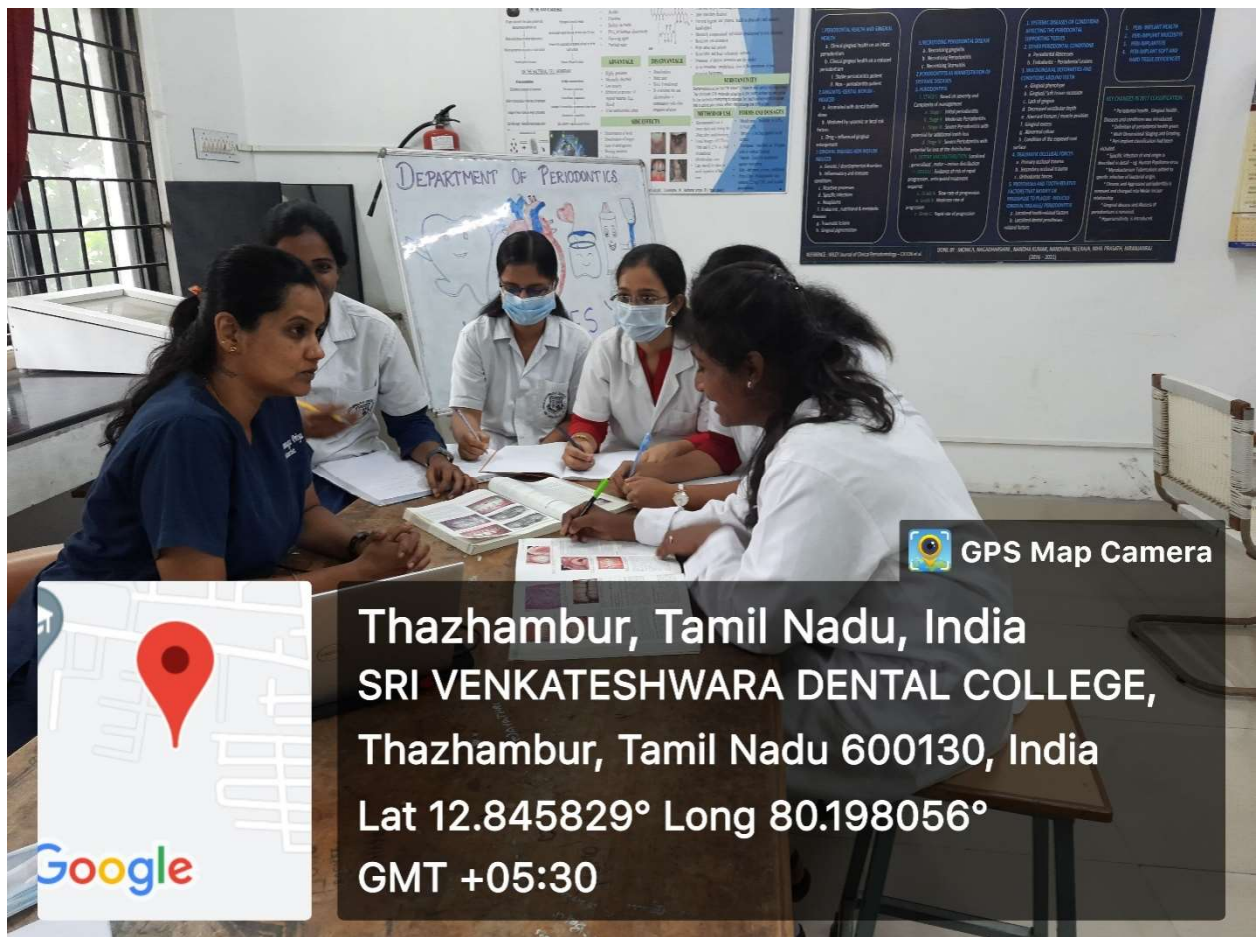


PRINCIPAL
SRI VENKATESWARA DENTAL COLLEGE & HOSPITAL
OFF. OMR NEAR - NAVALUR
THALAMBUR, CHENNAI-600 130.





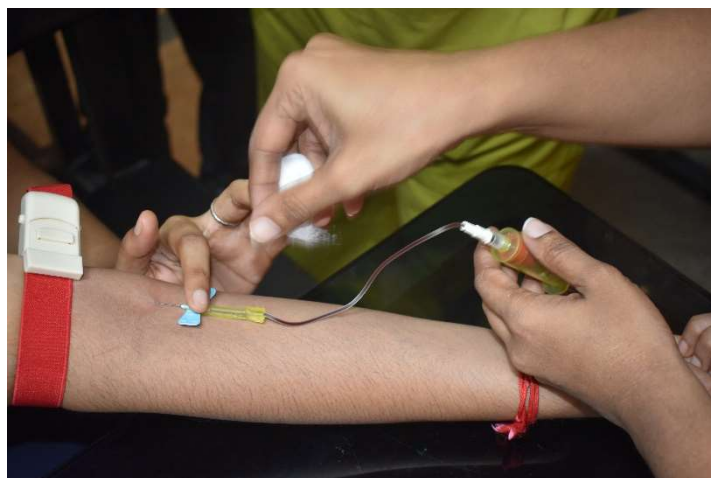GROUP DISCUSSION



A. J. Jeyaraj

PRINCIPAL
VENKATESHWARA DENTAL COLLEGE & HOSPITAL
OFF. OMR NEAR - NAVALUR
THALAMBUR, CHENNAI-600 130.

HANDS ON TRAINING



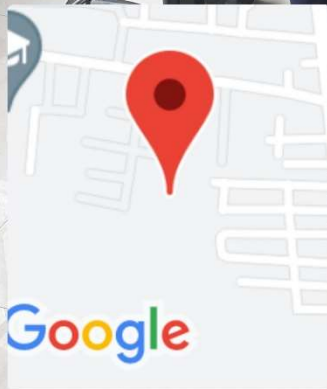
A. Jeyaraj

PRINCIPAL
SRI VENKATESWARA DENTAL COLLEGE & HOSPITAL
OFF. OMR NEAR - NAVALUR
THALAMBUR, CHENNAI-600 130.

LIBRARY DISCUSSION



GPS Map Camera

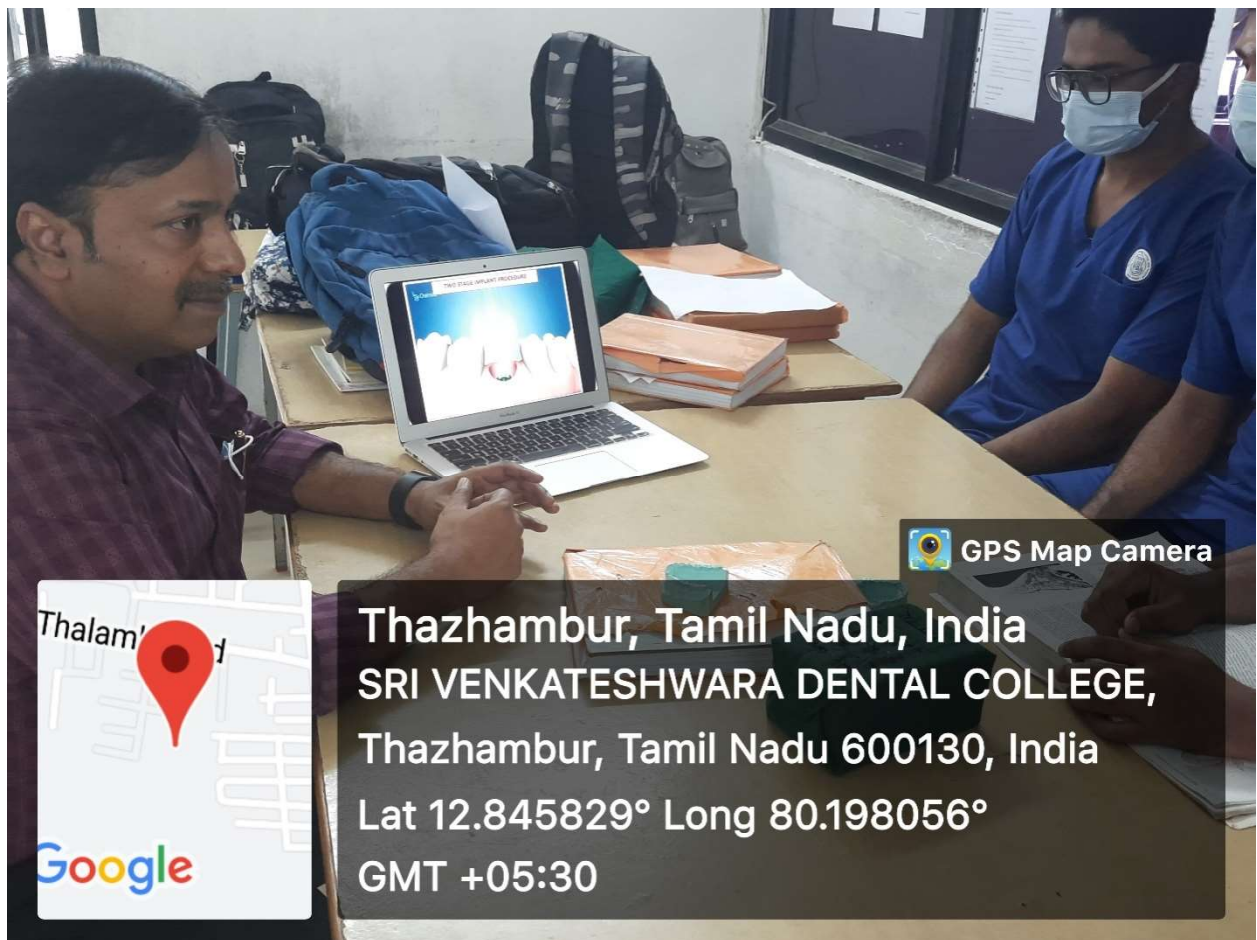


Thazhambur, Tamil Nadu, India
SRI VENKATESHWARA DENTAL COLLEGE,
Thazhambur, Tamil Nadu 600130, India
Lat 12.845829° Long 80.198056°
GMT +05:30

A handwritten signature in green ink, likely belonging to the Principal of the college.

PRINCIPAL
SRI VENKATESHWARA DENTAL COLLEGE & HOSPITAL
OFF. OMR NEAR - NAVALUR
THALAMBUR, CHENNAI-600 130.

PROBLEM SOLVING METHODOLOGY



PROJECT BASED LEARNING

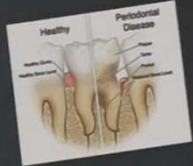

A. J. Jeyaraj

PRINCIPAL
SRI VENKATESHWARA DENTAL COLLEGE & HOSPITAL
OFF. OMR NEAR - NAVALUR
THALAMBUR, CHENNAI-600 130.

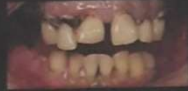


→ ITS EFFECTS ON THE PERIODONTIUM



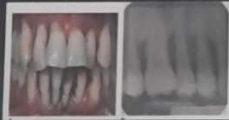Leads to

- Bad Breath
- Tooth discoloration
- Increased plaque and tartar
- Increased loss of bone within the jaw
- Increased risk of leukoplakia, (White patches inside the mouth)
- Increased risk of developing periodontal disease, a leading cause of tooth loss
- Delayed healing process following tooth extraction, periodontal treatment, or oral surgical procedures
- Increased risk of developing oral cancer



Pathology

- Smoking impairs the normal functions of the host response in neutralizing infection
- It alters the host response, resulting in destruction of the surrounding healthy periodontal tissues
- Decreases T lymphocytes



Hence, it would greatly benefit our patients if we, as dental professionals make a concerted effort to promote smoking - cessation programs as well as educate our community on the benefits of abstaining from smoking

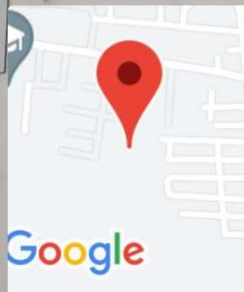
Done By: Divya Bharathi.S, Divya Bharathy.M, Durga Devi.G, Faiza.M, Fathima Farzana.A, Bharathi Rani, Devika Lakshmi, Fehar R.J, Virekhatya Solo, Sowmya Joseph (2009 - 2014)

Clinical Appearance

- Gingiva tends to be fibrotic with thickened / rolled margins
- Minimal gingiva redness or edema relative to disease severity
- Relatively severe and widespread disease (more probing depths, attachment loss, and tooth loss) compared to a person
- Proportionately greater periodontal probing depths in affected sites
- Gingival recession
- No association between periodontal status and plaque or calculus scores



GPS Map Camera



Thazhambur, Tamil Nadu, India
SRI VENKATESHWARA DENTAL COLLEGE,
Thazhambur, Tamil Nadu 600130, India
Lat 12.845829° Long 80.198056°
GMT +05:30

[Handwritten signature]

PRINCIPAL

SRI VENKATESHWARA DENTAL COLLEGE & HOSPITAL
OFF. OMR NEAR - NAVALUR
THALAMBUR, CHENNAI-600 130.

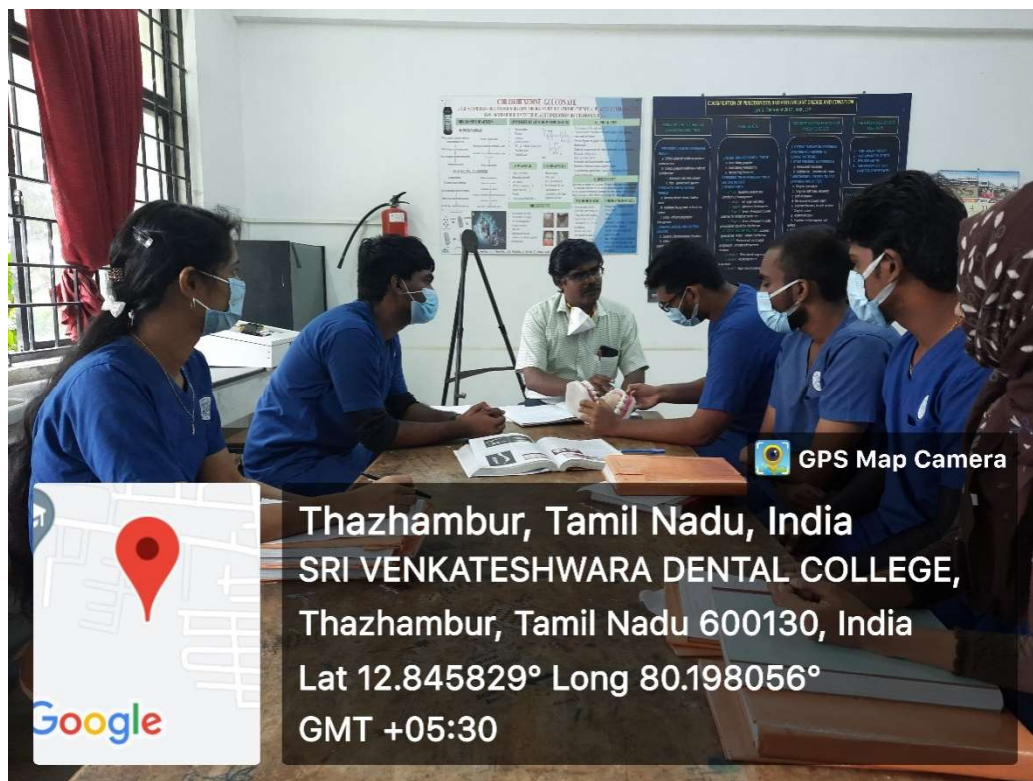
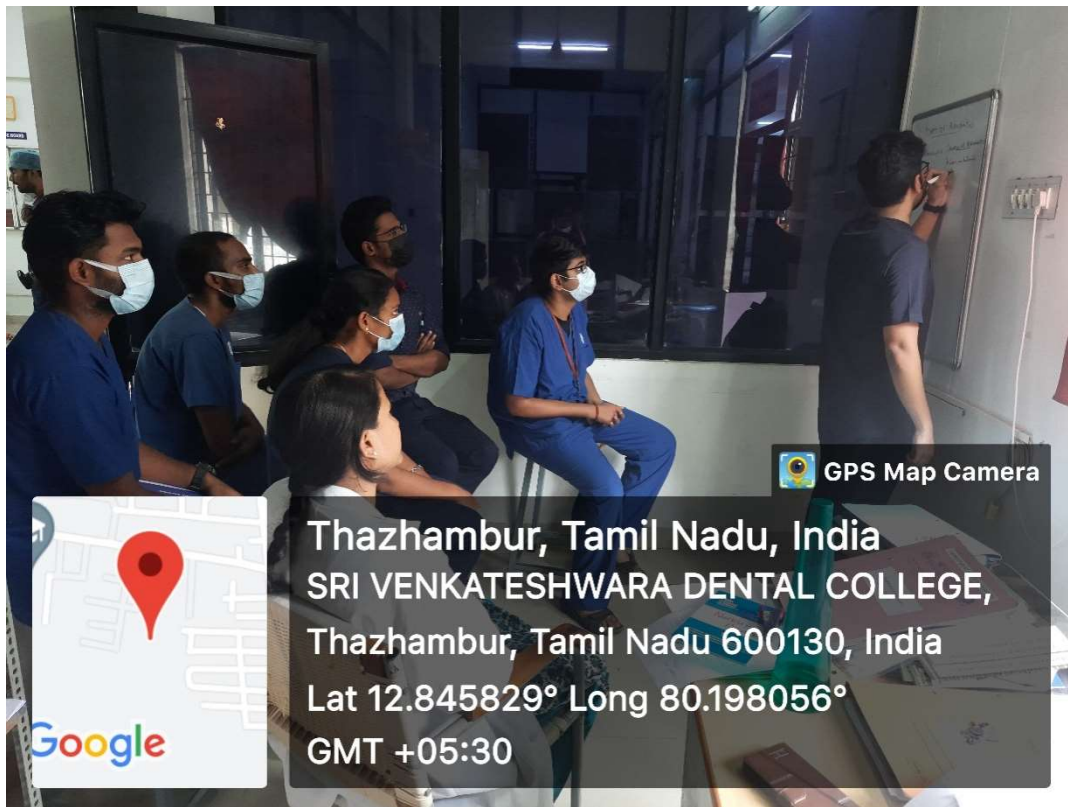
QUIZ



PRINCIPAL

SRI VENKATESWARA DENTAL COLLEGE & HOSPITAL
OFF. OMR NEAR - NAVALUR
THALAMBUR, CHENNAI-600 130.

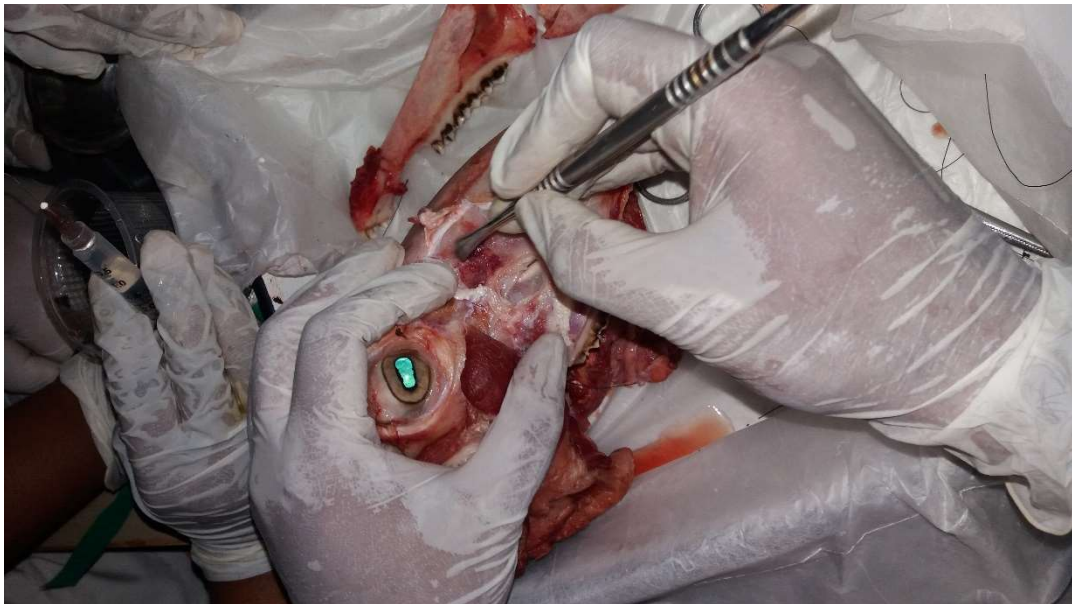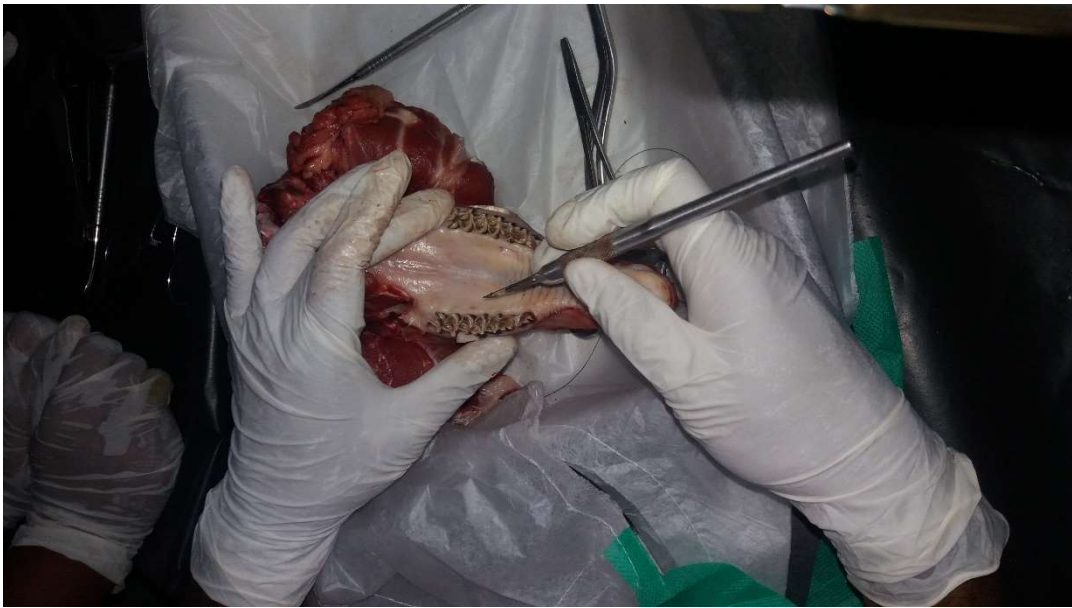PARTICIPATORY LEARNING



A. Jeyaraj

PRINCIPAL
SRI VENKATESHWARA DENTAL COLLEGE & HOSPITAL
OFF. OMR NEAR - NAVALUR
THALAMBUR, CHENNAI-600 130.

ANIMAL MODEL DEMONSTRATION



PHD NAAC PIC.pdf

PRINCIPAL

SRI VENKATESWARA DENTAL COLLEGE & HOSPITAL

OFF. OMR NEAR - NAVALUR

THALAMBUR, CHENNAI-600 130.